

## DIAGNOSTIC DILEMMA OF A DIAPHRAGMATIC HERNIA

Salman Yahya<sup>1</sup>, Sonia Zafar<sup>1</sup>, Hafsa S. Babar<sup>2</sup>

<sup>1</sup>Department of Anaesthesia and Pain Management, Shaukat Khanum Memorial Cancer Hospital and Research Centre, Lahore, Pakistan, <sup>2</sup>Department of Radiology, Shaukat Khanum Memorial Cancer Hospital and Research Centre, Lahore, Pakistan

Received: 04 July 2018 / Accepted: 17 September 2018

### Abstract

Diaphragmatic hernia post-oesophagectomy is a rare complication but a reality in its existence. It is typically difficult to diagnose but highly depends on keeping high index of suspicion. In our case report, a 45-year-old male who underwent oesophagectomy for oesophageal carcinoma remained disease free and stable in his 9-month follow-up, suddenly presented in the emergency department with the symptoms of shortness of breath, chest pain, vomiting and tachycardia. The case was typically complicated by the initial treatment given for acute ischaemia and cardiogenic shock. Radiological findings proved to be helpful and turning point in the diagnosis and overall management.

**Key words:** Diaphragmatic hernia, oesophagectomy, computed tomography

### Introduction

Diaphragm is our major muscle of respiration and its excursion along with chest wall expansion creates the negative intrathoracic pressure required for inhalation. This same pressure can cause prolapse of retroperitoneal or intra-abdominal contents into the thoracic cavity through any diaphragmatic defect, either congenital or acquired.<sup>[1]</sup>

Aetiology for acquired diaphragmatic rupture is mostly penetrating or blunt injury, but it can also be iatrogenic following cardiothoracic and abdominal procedures.<sup>[2]</sup> The complications arising from rupture to herniation of contents can lead to significant morbidity and mortality. This rare condition is often misdiagnosed due to its unusual clinical manifestations and delayed recognition can lead to complications such as strangulation infarction and perforation. Prompt diagnosis and surgical repair are recommended, and traditionally, repair is done by laparotomy or thoracotomy or both.

Three-stage oesophagectomy is a well-known procedure done for tumours of the upper thoracic oesophagus

where oesophagectomy can be performed through a right thoracotomy, then by simultaneous left cervical and abdominal incisions the stomach can be prepared and delivered up to the neck for anastomosis (McKeown's procedure).<sup>[3]</sup>

### Case Report

A 45-year-old male presented in February 2017, with complaint of progressive dysphagia and epigastric pain for 6 months was diagnosed with squamous cell carcinoma of distal oesophagus. On endoscopy, the tumour was found to be starting at 31 cm from the incisors and extending down to 38 cm with the GO junction present at 40 cm. Subsequent staging with positron emission tomography-computed tomography (PET-CT) scan showed a cT3N1Mx tumour. Neoadjuvant chemotherapy and radiation followed by surgical intervention were suggested as the course of treatment by the multidisciplinary tumour board.

He proceeded to neoadjuvant therapy with carboplatin and paclitaxel along with radiotherapy, but regimen was withheld on the fifth cycle due to complaint of non-herpetic rash and low platelet count. He was fed enterally with a PEG tube and repeat PET-CT scan showed stable disease. Following a period of nutritional support, the patient proceeded to surgery after reassessment.

**Correspondence:** Dr. Salman Yahya, Department of Anaesthesia, Shaukat Khanum Memorial Cancer Hospital and Research Centre, Lahore, Pakistan.  
Email: khattakyahya@gmail.com

Laparoscopic three-stage oesophagectomy was successfully done in August 2017. The patient was discharged on the 7<sup>th</sup> post-operative day with 2 days stay in the intensive care unit. He was kept on 3 monthly surveillance and follow-up both by the oncologist and surgeon.

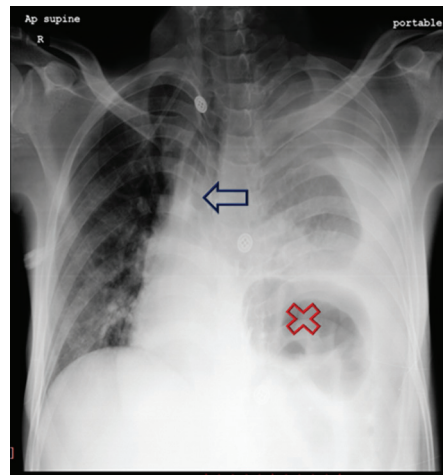
He remained asymptomatic and disease free on each follow-up till he presented in the emergency department with complaint of epigastric and left-sided chest pain for the past 4 days accompanied by 3–4 episodes of non-projectile vomiting per day, constipation and orthopnoea. Pain was continuous, dull, moderate to severe in intensity and not associated with exertion. On examination, the patient was frail, cachectic, conscious and oriented but short of breath and unable to lie flat. He was found to be tachycardiac (heart rate 156 beats/min), hypotensive with systolic pressure around 80 mmHg and hypoxic, saturation 84% on 4 L of oxygen. There was decreased air entry in the left lower and middle zone and abdomen was soft but tender in the left hypochondrium with sluggish bowel sounds.

Initial electrocardiogram showed T-wave inversions and ST segment depression in leads V2–V3, Trop I value was 0.7 with ejection fraction of 40–45% on echo raising the suspicion of cardiogenic shock secondary to ischemia. 2 L of crystalloids were rushed to the patient, oxygen through BIPAP, clopidogrel and aspirin 300 mg each were given immediately in the emergency department after cardiology input. Arterial blood gas showed respiratory alkalosis.

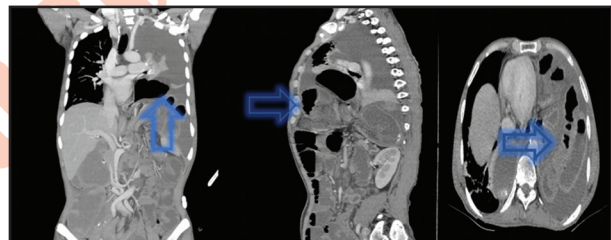
Chest X-ray [Figure 1] depicted whiteout left lung with a few air-fluid levels and mediastinal shift. Treatment was then shifted on lines of hypoxemic respiratory failure secondary to massive pleural effusion and urgent pleural tap was planned.

CT chest and abdomen with contrast finally revealed strangulated diaphragmatic hernia containing small bowel loops in the left hemithorax with collapse of the left lung and mediastinal shift [Figure 2].

The patient was optimized to the best possible levels with transfusions and fluid resuscitation and shifted to operating room for laparoscopic repair of 4 cm defect in diaphragm, segmental resection of gangrenous bowel,



**Figure 1:** Chest X-ray showing gut loops in the left hemithorax (shown as X) and significant white-out left lung and mediastinal shift (shown as ←)



**Figure 2:** Coronal sagittal and cross-sectional reformatted images through chest and abdomen demonstrate multiple hypoenhancing bowel loops extending into the left hemithorax. Large left pleural effusion is most likely secondary to compromised bowel loops

ileostomy and left-sided chest tube insertion was done. Awake arterial line was placed and rapid sequence induction was done which remained uneventful. The situation started to improve quickly once the gangrenous gut was removed and defect repaired.

The post-operative period was complicated by intra-abdominal hematoma formation causing haemoglobin level to drop from 7.5 g/dL to 5.1 g/dL within a few hours. The patient underwent exploratory laparotomy on the same day on double pressor supports (Noradrenaline + Phenyl epinephrine), along with ventilatory support, to find out the source of bleeding. Laboratory reports showed a decreasing trend of platelet count with fall from 70 to 47, despite transfusion of packed red blood cells preoperatively as well as mega unit and whole blood transfusion post-reexploration. He remained in intensive care unit for 3 days after abdominal washout, and

later, post-operative recovery was gradual but remained uneventful.

### Discussion

Trans-hiatal hernia is a rare, most often missed or misdiagnosed complication of thoracoabdominal procedures.<sup>[4]</sup> All patients having a history of surgical intervention on oesophagus, complaining of non-specific epigastric pain, suspicion of hiatal or diaphragmatic hernia should always be considered. The list of differentials must consider diaphragmatic hernia, on the basis of high clinical index of suspicion and history, for early and effective management.<sup>[5]</sup>

Ruptures are typically located in the posterolateral aspect of the hemidiaphragm because this area is embryologically weaker and more on the left side as the right diaphragm can withstand greater changes in the intra-abdominal pressure gradient due to its protection by the liver.<sup>[6]</sup>

Small diaphragmatic tears may enlarge over time, allowing herniation of abdominal organs such as stomach, spleen colon small bowel or liver into the thoracic cavity, leading to mediastinal shift causing respiratory and circulatory disturbances.<sup>[7]</sup> This masks the primary underlying pathology and plays a huge part in greater incidence of complications. Moreover, thus, delayed diagnosis can be catastrophic for such patients. Price *et al.*<sup>[8]</sup> in a large case series of 2182 patients, who underwent oesophagectomy, found 15 patients (0.69%) required surgical exploration for symptomatic diaphragmatic hernia as initial surgery complication.

Imaging plays a crucial role. Chest X-ray may demonstrate an elevated hemidiaphragm, distortion of the diaphragmatic margin, visceral content in the thorax, loculated left pneumothorax and mediastinal shift, and when a nasogastric tube is in place, it can be seen in the thorax. A chest CT scan has 61–71% sensitivity and 87–100% specificity for acute and chronic diaphragmatic herniation.<sup>[9]</sup>

In our case, CT scan findings proved to be the turning point of our treatment strategy. Uncertainty in the course of management was the main causative factor of post-operative complications encountered in this case. Significant bleeding caused by high loading dose of antiplatelet and antithrombotic agents given

initially resulted in repeated transfusions added further nuisance.

For surgical repair, laparotomy is preferred for unstable patients, with associated intra-abdominal injuries, whereas thoracotomy can be done for stable patients without intra-abdominal injuries, contralateral diaphragmatic injuries or a delayed diagnosis.<sup>[10]</sup>

### Conclusion

Surgeons, emergency physicians and intensivists should maintain a high suspicion for diaphragmatic hernia, especially a patient presenting with dysphagia, shortness of breath or chest pain-related symptoms and who already has undergone upper gastrointestinal or diaphragmatic surgeries. Radiological follow-ups and keeping low threshold for suspicion of such defects are emphasised to detect hiatal herniation at an earlier stage.

### Conflict of Interest

The authors declare that they have no conflict of interest.

### References

1. Lu J, Wang B, Che X, *et al.* Delayed traumatic diaphragmatic hernia: A case-series report and literature review. *Medicine (Baltimore)* 2016;95:e4362.
2. Grimes OF. Traumatic injuries of the diaphragm. *Diaphragmatic hernia.* *Am J Surg* 1974;128:175-81.
3. Houston MG, Kennedy JA. Acute diaphragmatic hernia post-esophagectomy. *J Case Rep Images Surg* 2016;2:67-9.
4. Szwalbe K, Misiak P, Terlecki A. Post-traumatic peritoneo-pericardial diaphragmatic hernia: A case report. *J Trauma Treat* 2017;6:364.
5. Testini M, Girardi A, Isernia RM, *et al.* Emergency surgery due to diaphragmatic hernia: Case series and review. *World J Emerg Surg* 2017;12:23.
6. DeAlwis K, Mitsunaga EM. Sudden death due to nontraumatic diaphragmatic hernia in an adult. *Am J Forensic Med Pathol* 2009;30:366-8.
7. Wigley J, Noble F, King A. Thoracoabdominal herniation-but not as you know it. *Ann R Coll Surg Engl* 2014;96:e1-2.
8. Price TN, Allen MS, Nichols FC 3<sup>rd</sup>, *et al.* Hiatal hernia after esophagectomy: Analysis of 2,182 esophagectomies from a single institution. *Ann Thorac Surg* 2011;92:2041-5.
9. Ganeshan DM, Correa AM, Bhosale P, *et al.* Diaphragmatic hernia after esophagectomy in 440 patients with long-term follow-up. *Ann Thorac Surg* 2013;96:1138-45.
10. Crespini OM, Farjah F, Cuevas C, *et al.* Hiatal herniation after transhiatal esophagectomy: An underreported complication. *J Gastrointest Surg* 2016;20:231-6.