

Follicular Lymphoma of Breast: A Case Report from Pakistan

Namra Urooj^{1*}, Umair Ahmed², Amina Khan¹, Zulqarnain Chaudhry¹, Muhammad Asad Parvaiz¹

¹Department of Surgical Oncology, Shaukat Khanum Memorial Cancer Hospital and Research Centre, Lahore, Pakistan, ²Department of Medical Oncology, Shaukat Khanum Memorial Cancer Hospital and Research Centre, Lahore, Pakistan

Received: 10 May 2022/Accepted: 02 June 2022



OPEN ACCESS

Correspondence:

Namra Urooj, 7-A Block R-3, Johar Town, Lahore - 54000, Pakistan.

E-mail: Namraurooj@skm.org.pk

Citation: Urooj N, Ahmed U, Khan A, Chaudhry Z, Parvaiz MA. Follicular Lymphoma of Breast: A Case Report from Pakistan. J Cancer Allied Spec [Internet]. 2022;8(2):1-5.

<https://doi.org/10.37029/jcas.v8i2.471>

Copyright: © 2022 Urooj N, et al. This is an open access article distributed under the terms of the [Creative Commons Attribution License](https://creativecommons.org/licenses/by/4.0/), which permits unrestricted use, distribution, and reproduction in any medium, provided the original author and source are credited.

Funding: This research received no specific grant from any funding agency in the public, commercial or not-for-profit sectors.

Competing interest: Nil.

Abstract

Introduction: Breast lymphoma (BL) is a rare breast tumour and accounts for <1% of all breast malignancies. It is further categorised into primary BL and secondary BL. This manuscript presents a case report of a patient diagnosed with secondary BL. **Case Description:** A 51-year-old female presented in the one-stop breast clinic with 6-month history of having a static and painless left breast lump. Mass was firm, non-tender and 2 cm in size. It was not adherent to skin or muscle and it was present in the upper outer quadrant of the left breast. Mammo-sonography revealed a circumscribed mass of 17 mm in the outer quadrant of the left breast. There were enlarged ipsilateral lymph nodes. Core biopsy suggested atypical lymphoid infiltrates. She underwent wide local excision of breast and axillary nodal mass. The definitive histological diagnosis revealed non-Hodgkin's follicular lymphoma grade 2/3. Staging computed tomography scan features were suggestive of cervical lymphadenopathy. Hence, staging workup proved this to be a case of secondary BL. **Practical Implication:** The early diagnosis of BL is highly relevant. Its diagnosis is challenging due to non-specific clinical presentation and imaging features. Commonly FL is diagnosed on excisional biopsy or after wide local breast mass excision. Primary and secondary lymphomas, though rare, should be considered in the differential diagnosis of breast malignancies.

Keywords: Breast cancer, follicular, lymphoma, non-Hodgkin's

Introduction

Breast lymphoma (BL) is a rare breast tumour and arises in breast lymphoid tissue. It accounts for <1% of all breast malignancies.^[1] BL is subcategorised into primary BL (PBL) and secondary BL (SBL). Lymphoma arising from *de nova* in the breast is considered to be PBL. However, lymphoma arising elsewhere in the body and spreading to the breast is SBL. PBL is much less common than SBL.^[2]

In 1972, Wiseman and Liao defined PBL as any lesion with an adequate pathologic specimen; both mammary tissue and lymphomatous infiltrate in closer relation to each other; no evidence of widespread disease and no prior diagnosis of extramammary lymphoma.^[3] In studies, PBL has also been recently reported to be of lower grade than SBL.^[4]

Although SBLs are rare, they represent the largest group of metastatic tumours of the breast.^[1] The

most common cancers to metastasise to the breast are lymphoma, malignant melanoma, lung cancer, ovarian carcinoma, soft-tissue sarcoma and gastrointestinal and genitourinary tumours.^[5]

Lymphomas are described as a cancer of the lymphatic system and can be subdivided approximately into 40% Hodgkin's lymphoma and 60% non-Hodgkin's lymphoma (NHL).^[2]

It arises in nodal tissue as well as in extranodal lymphatic tissue. The incidence of extranodal NHL is remarkably increasing. Organs having areas of lymphoid tissue such as the gastrointestinal tract, skin, bone, brain and Waldeyer's ring have been described as a site of extranodal involvement.^[2] However, NHL may rarely occur in tissues that do not usually contain lymphoid areas, such as the breast. BL is 0.4% of all NHL and <3% of extranodal NHL.^[6]

There are multiple subtypes of NHL. Diffuse large B cell lymphoma (DLBCL) is the most common histological subtype, comprised of 30%, followed by follicular lymphoma (FL), which accounts for 22%, while the rest of the entities comprise 21%.^[7]

We report a case of FL of the breast found incidentally on wide local excision of a patient who presented with a suspicious breast mass. No case report of FL of the breast has been reported from Pakistan. We believe that this case report provides helpful context about the histopathological subtypes and management of this rare disease.

Case Description

The patient was a 51-year-old female who presented with a left breast lump in the One-Stop Breast Clinic of Shaukat Khanum Memorial Cancer Hospital and Research Center, Lahore, Pakistan. In the clinic, she had a standard triple assessment of breast mass.

Mass was present for the past 6 months, remained static, painless and with no other palpable lump elsewhere. There was no history of nipple discharge or any nipple changes. She was the mother of two kids. Her first child was born at the age of 25 years,

and she breast-fed both her kids. She gave a history of lumpectomy in the ipsilateral breast 5 years ago, of which the report was not available. She denied a history of oral contraceptive intake or a family history of breast cancer. She attained menarche at 14 years. Mass was firm, painless and 2 cm in size. It was not adherent to skin or muscle and was present in the upper outer quadrant of the left breast. The ipsilateral axilla was unremarkable and the contralateral breast and axilla. The rest of the physical examination was normal.

Diagnosis and management

A radiological investigation was performed as part of the triple assessment of breast mass. The mammogram revealed heterogeneous dense parenchyma. It demonstrated post-excisional architectural distortion in the lower central quadrant. There were scattered benign calcific foci. No pleomorphic calcification was seen. A well-circumscribed mass was seen on the mediolateral oblique view in the outer posterior of the left breast. The overlying skin and nipple-areolar complex were normal. The left axilla showed enlarged lymph nodes. [Figure 1a and b] Ultrasonography demonstrated a circumscribed hypoechoic mass of 1.7 cm in the middle outer quadrant. Multiple suspicious lymph nodes, the largest measuring 2 cm, were observed in the ipsilateral axilla.

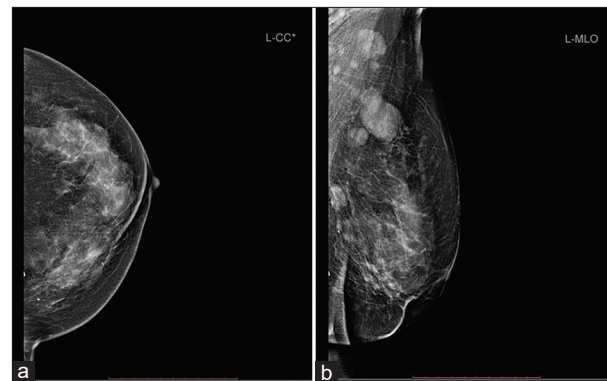


Figure 1: (a) Craniocaudal (CC) view mammogram of the left breast shows heterogeneous dense breast parenchyma and mass not visualized on this view. (b) Mediolateral oblique view mammogram shows well circumscribed mass in central posterior breast. The left axilla shows enlarged lymph nodes.

The core of the left breast mass suggested extensive necrosis with atypical lymphoid infiltrate. Fine needle aspiration cytology of axillary lymph node showed reactive lymphoid tissue.

The case was reviewed at a multidisciplinary tumour board meeting and discussed in detail with radiology, pathology, general surgery, radiation oncology and medical oncology specialists. On recommendation, wide local excision of breast mass and axillary nodal mass was performed.

Microscopic examination of breast lumpectomy and axillary lump excision revealed lymph nodes with neoplastic follicles comprising of atypical small lymphoid cells and approximately 8–9 centroblasts in a high-power field [Figure 2a and b]. Immunophenotypic analysis was performed on paraffin-embedded tissue sections and a strong positive stain for CD20, CD10, BCL2 and BCL6 antibodies was demonstrated [Figure 3a and b]. The definitive histological diagnosis revealed non-Hodgkin's follicular lymphoma grade 2/3.

A further staging workup was performed to categorise into PBL and SBL. A computed tomography study of the chest, abdomen and pelvis revealed left-sided cervical lymphadenopathy suggesting lymphoma. Bone marrow aspirate showed lymphoid cells indicating bone marrow involvement with the lymphoma. The patient was planned for six cycles of Rituximab, a monoclonal antibody, following surgery.

Discussion

BL represents 0.5% of all breast malignancies, as reported in the literature.^[4] Other investigators reported that BL constituted 0.21% of all malignant neoplasms of the breast.^[8] Similarly, it represents 1.13% of all non-Hodgkin's lymphomas. Primary FL of the breast is a rare disease with no extramammary disease involvement. Secondary FL of the breast is a relatively common entity with extramammary spread by FL, that is, nodes, spleen, liver and bone marrow.^[2]

Therefore, metastatic disease breast is often an unexpected diagnosis in a female patient presenting with a breast mass. The most common source is spread from contralateral breast carcinoma.^[2] The most common extramammary cancer metastasizing to the breast is lymphoma.^[9] SBL accounts for 17% of metastatic diseases in the breast.^[9]

In PBL and SBL, diffuse large B-cell lymphoma is the most common form of NHL, followed by FL. FL occurs in all races and geographic locations. In the United States, as a whole, FL accounts for approximately 35% of NHLs and has an estimated incidence of 3.18 cases/100,000 people. FL is thought to arise from germinal centre B cells, which include both centrocytes (small-cleaved follicular centre cells) and centroblasts (large non-cleaved follicular centre cells). The pathogenesis of FL is incompletely understood. Approximately 85% of FL have the t(14;18), which results in the juxtaposition

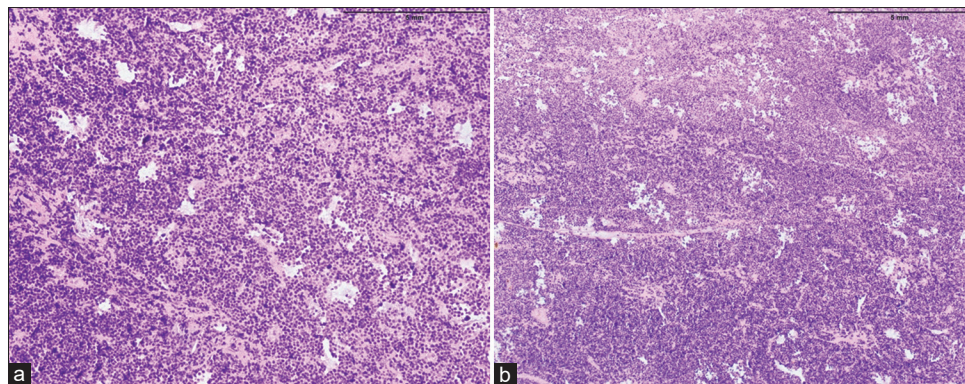


Figure 2: (a and b) Hematoxylin-eosin [H-E] stain shows complete effacement of lymph node architecture by neoplastic follicles composed of mixture of centrocytes and centroblasts. There is lack of tangible body macrophages and attenuated mantle zones

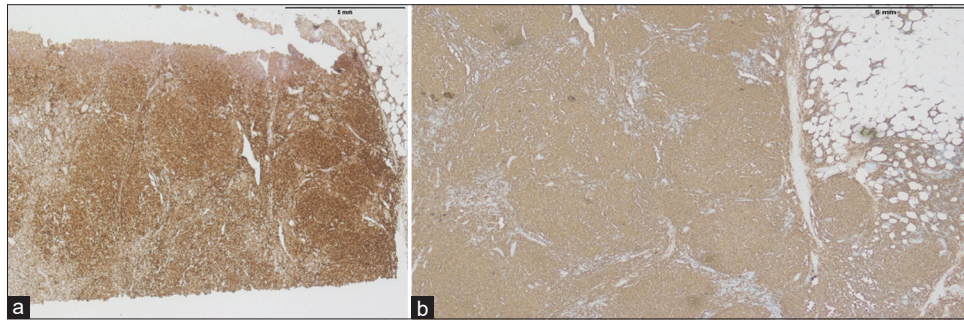


Figure 3: (a) Immunohistochemical (IHC) staining revealed the expression of CD20 by neoplastic B lymphocytes (magnification $\times 20$), (b) IHC staining with BCL2 highlights neoplastic B lymphocytes (magnification $\times 20$)

of the B cell leukaemia/lymphoma 2 (BCL2) gene with regulatory elements of the immunoglobulin heavy chain gene (IGH).^[10]

Our patient was presented with a breast mass of 6-month duration. In the past literature, most FL patients present painless mass in the breast associated with cervical, axillary, inguinal and/or femoral regions. Only approximately 20% present with B symptoms (i.e., fevers, night sweats or unintentional weight loss). In our case, there was no history of B symptoms and lymphadenopathy. Involvement of organs other than the lymphatic organs or bone marrow is uncommon.

The imaging features of BL are not characteristic and are mostly indistinguishable from mammary carcinoma. Among the cases reported in the literature on the mammogram, the most common finding consisted of the presence of high-density masses with circumscribed or indistinct margins. On ultrasound, hypoechoic masses and indistinct diffuse infiltrative patterns are mainly observed.^[9]

In our population, commonly FL is diagnosed on excisional biopsy or wide local breast mass excision.^[8] A core biopsy was inconclusive in our case. The diagnosis of systemic FL is made based on the evaluation of tissue biopsy. In classic cases, the tumour has a distinctly nodular growth pattern and comprises a mixture of centrocytes and centroblasts. Mitoses and apoptotic cells, common in reactive follicles, are infrequently seen.^[10]

Characteristically, the tumour cells express monotypic immunoglobulin light chain, CD19, CD20, CD10 and BCL6 and are negative for CD5 and CD23. The vast majority (>85 percent) of tumours express BCL2 as a result of the t(14; 18), which can be detected by fluorescence *in situ* hybridization or by polymerase chain reaction.^[11]

To date, limited data regarding prevalence, types or treatment outcomes of BL have been reported from Pakistan. We could find only two studies from Pakistan examining the frequency, characteristics categories and outcome of treatment modalities regarding this specific breast malignancy. One of the studies is from a tertiary care hospital in Karachi and the other is from our institute, as summarised in Table 1.^[4,8]

Nausheen *et al.* reported a single-centre study of 30 cases of BL over 12 years. Diffuse large B cell NHL was the most common cancer in their study and comprised 65.5% of the total cases. It was followed by 21% of NHL not otherwise specified, and the rest were other types of NHL. There was no case of FL breast in this study.^[4]

Another study was conducted 8 years back in our institute. The authors retrospectively analysed data on BL. Razia *et al.* described 27 cases (0.21%) with BL that presented to the hospital over a 20-year window. The most common histological subtype was DLBCL 16 (59.3%). The rest were Hodgkin's lymphoma, small lymphocytic lymphoma, anaplastic large cell lymphoma, FL, low-grade B

Table 1: Summary of studies on breast lymphoma from Pakistan

Study	Nausheen <i>et al.</i>	Razia <i>et al.</i>
Publishing year	2006	2016
Institute	Agha Khan Hospital, Karachi	Shaukat Khanum Memorial Cancer Hospital and Research Centre, Lahore
No. of BL patients	30	27
No. of FL patients	None	One

cell with IDC, low-grade B cell lymphoma, lymphoblastic lymphoma and mucosa-associated lymphoid tissue lymphoma.^[8] The detail of the single case of FL was not described.

The literature is inconclusive regarding the treatment of BL. In addition, there are no standard treatment guidelines for its management. All therapeutic modalities, including chemotherapy, surgery and radiation therapy, have been used to manage patients. Staging axilla is also controversial in all available data.^[9] Treatment is mainly directed at primary malignancy in the case of SBL. As in this particular case, wide local excision of the lesion followed by chemotherapy to target the primary lesion was done.

Prognosis is mainly dependent on lymphoma type, grade and stage. Tumour size has shown no correlation with prognosis. SBL demonstrates a poor prognosis compared to that of PBL and breast carcinoma, which is not unexpected given its advanced metastatic stage at clinical presentation.^[12]

The early diagnosis of BL is highly relevant. Non-specific clinical presentation and imaging features require clinical history review, multimodality imaging approach and histopathology for diagnosis and management. Primary and secondary lymphomas, though rare, should be considered in the differential diagnosis of breast malignancies.

Acknowledgment

Dr Nida (Resident Pathology) helped in providing slides and their descriptions.

References

1. Topalovski M, Crisan D, Mattson JC. Lymphoma of the breast: A clinicopathologic study of primary and secondary cases. *Arch Pathol Lab Med* 1999;123:1208-18.
2. Pasta V, Midulla C, Monti M, Martelli M, Torcasio A, Stella S. Unusual breast tumors: Primary lymphoma. A case report. *Tumori J* 2004;90:507-9.
3. Wiseman C, Liao KT. Primary lymphoma of the breast. *Cancer* 1972;29:1705-12.
4. Yaqoob N, Pervez S, Kayani N, Ahmed R, Ahmed Z, Hasan S. Frequency and characteristics of breast lymphomas presenting to a tertiary care hospital, Pakistan. *J Pak Med Assoc* 2006;56:441.
5. Akcay MN Metastatic disease in the breast. *Breast* 2002;11:526-8.
6. Linet MS, Morton LM, Wang SS, Devesa SS, Hartge P, Weisenburger DD. Lymphoma incidence patterns by WHO subtype in the United States, 1992-2001. *Blood* 2006;107:265-76.
7. Armitage JO. A clinical evaluation of the international lymphoma study group classification of non-Hodgkin's lymphoma. *Blood* 1997;89:3909-18.
8. Bano R, Zafar W, Khan AI, Fiaz SA, Abid M, Chaudhary MZ, *et al.* Breast lymphoma treatment outcomes in a Pakistani population: 20 years of experience at a single center. *Asian Pac J Cancer Prev* 2016;17:3631-5.
9. Raj SD, Shurafa M, Shah Z, Raj KM, Fishman MD, Dialani VM. Primary and secondary breast lymphoma: Clinical, pathologic, and multimodality imaging review. *Radiographics* 2019;39:610-25.
10. Freedman AS, Aster JC. Clinical Manifestations, Pathologic Features, Diagnosis, and Prognosis of Follicular Lymphoma. *United States: UpToDate*; 2021.
11. Khanlari M, Chapman JR Follicular lymphoma: Updates for pathologists. *J Pathol Transl Med* 2022;56:1.
12. Loughrey MB, Windrum P, Catherwood MA, Alexander HD, Markey GM, McManus DT, *et al.* WHO reclassification of breast lymphomas. *J Clin Pathol* 2004;57:1213-4.

Authors' Contributions

Conceived and designed the analysis: NU, Collected the data: NU and UA, Contributed data or analysis tools: AK, ZC and MAP, Performed the analysis: N/A, Wrote the paper: NU, UA, AK, ZC and MAP.